



G.DURAND . J.GIRON . P.FAJADET

Homme de 38 ans

C1 : souffle « cardiaque »



5.0 kV 11.75% (NO Fil.)
: 0.0

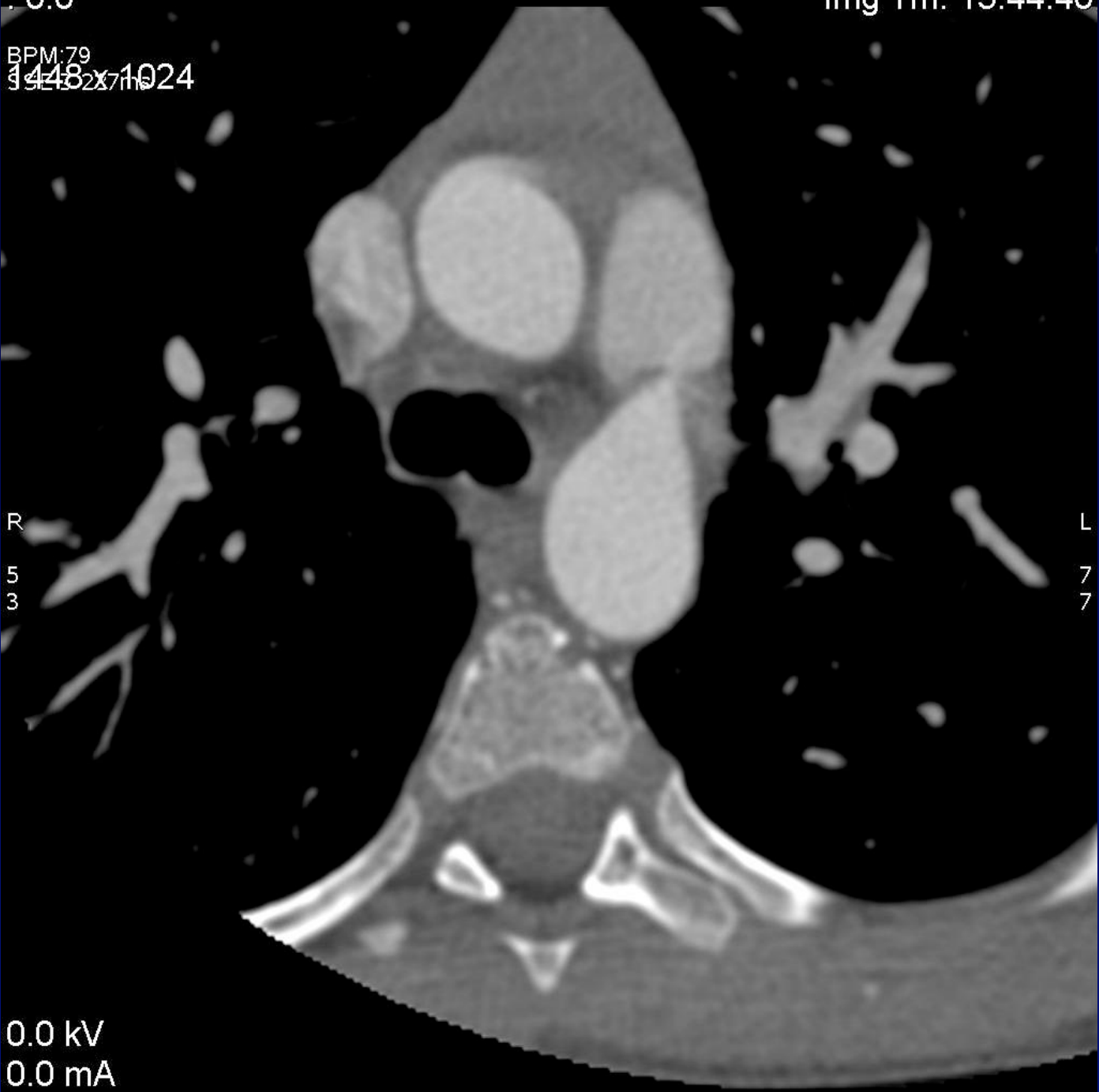Img Tm: 15:44:40

BPM: 79
1448x1024
1925x716

R
5
3

L
7
7

0.0 kV
0.0 mA
Tilt: 0.0





124 X 512

Volume Rendering No cut

Exp: Feb 25 2009

DFOV 6,5 cm
STND Ph:75%

A
I
R

P
S
I

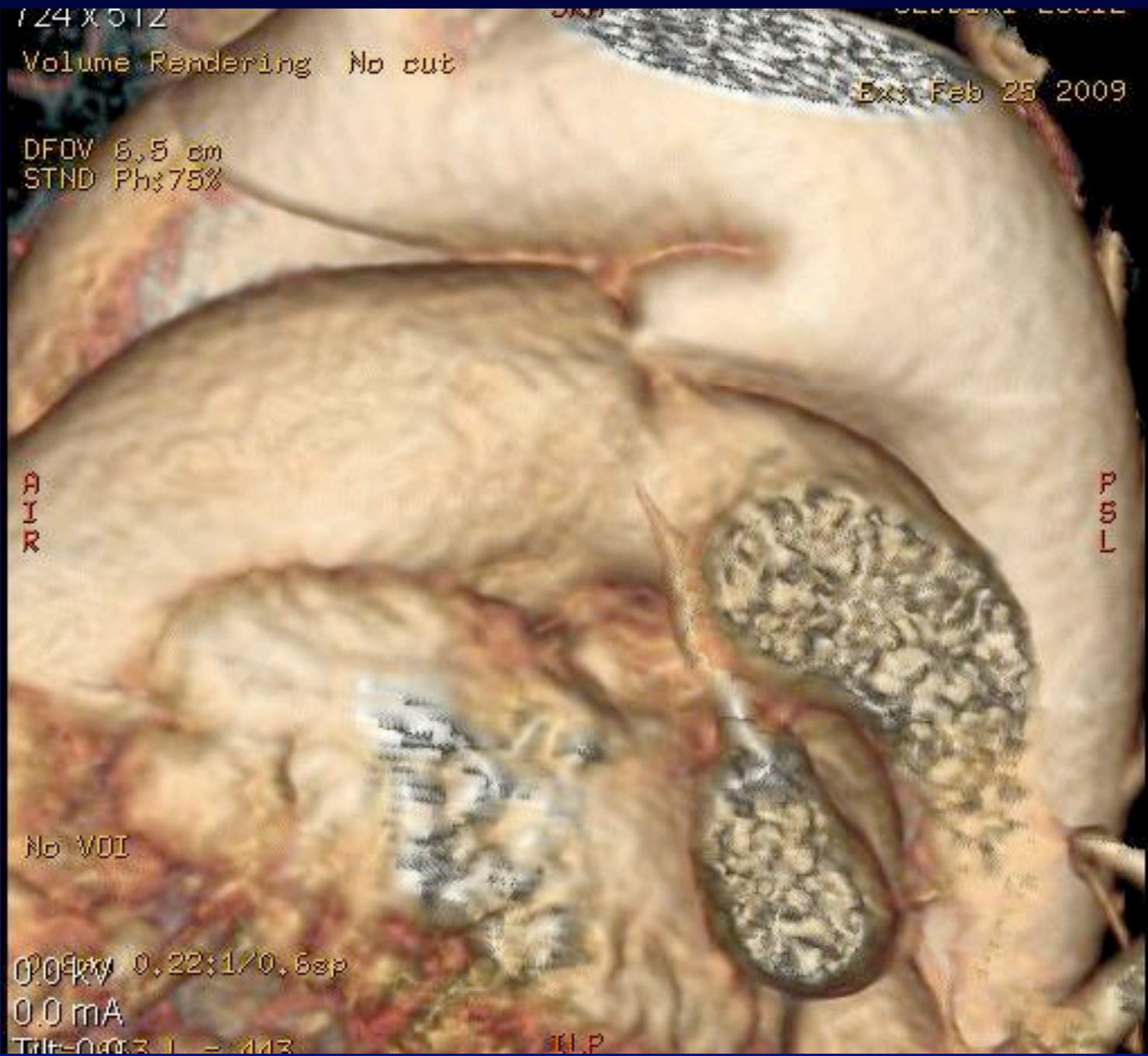No VDI

0.22:1/0.5sp

0.0 mA

Tilt=0.0031 = 443

361 P





DFOV 13.0 cm
STND Ph:75%

ISD

PIL

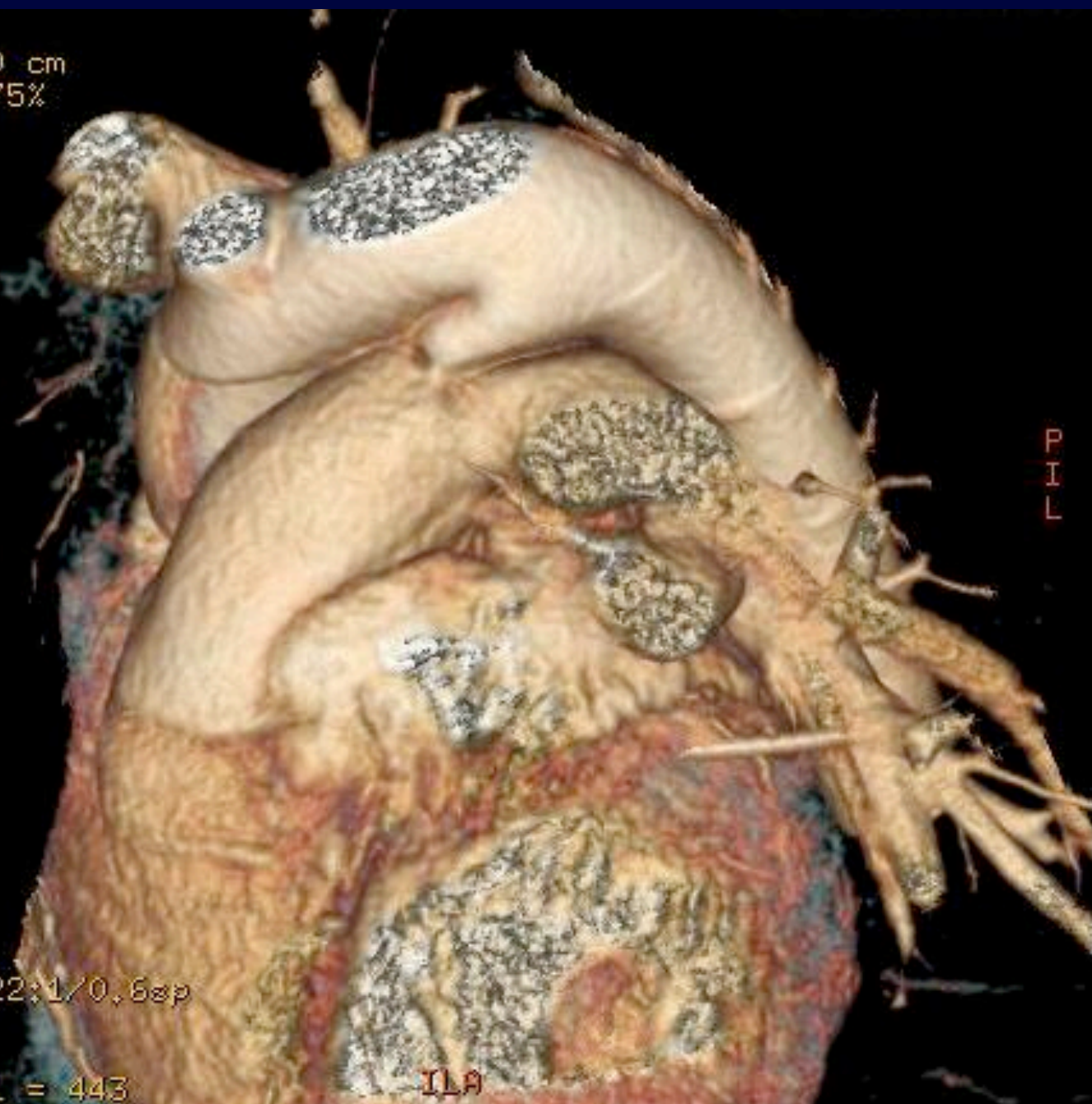
No VOI

0.09x 0.22:1/0.6ap

0.0 mA

Tilt=003 L = 443

ILA





Diagnostic ?



Diagnostic

Canal artériel Perméable



0.0

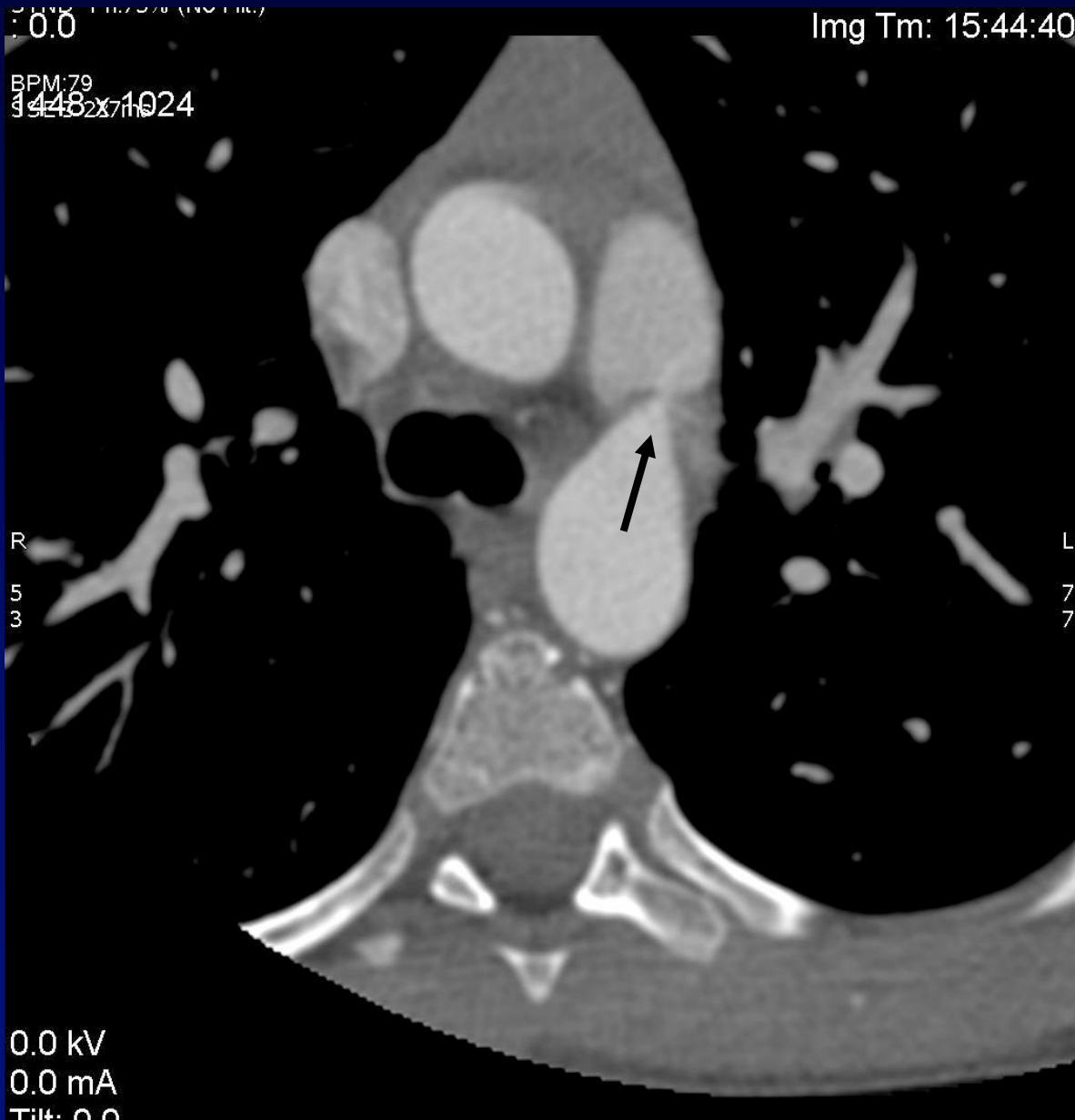Img Tm: 15:44:40

BPM: 79
1448x71024

R
5
3

L
7
7

0.0 kV
0.0 mA
Tilt: 0.0





Risque d'hyper débit Pulmonaire